

Case report

Open Access

Metastatic sweat gland adenocarcinoma: A clinico-pathological dilemma

Chintamani*¹, RD Sharma¹, Rohini Badran¹, Vinay Singhal¹, Sunita Saxena² and Anju Bansal²

Address: ¹Department of Surgery, Vardhman Mahavir Medical College & Safdarjang Hospital, New Delhi 110023 India and ²Institute of Pathology, Indian Council of Medical Research (ICMR), New Delhi 110023 India

Email: Chintamani* - chintamani7@rediffmail.com; RD Sharma - sririshabha@hotmail.com; Rohini Badran - chintamani@doctor.com; Vinay Singhal - chintamani@doctor.com; Sunita Saxena - mrinal5@rediffmail.com; Anju Bansal - mrinal5@rediffmail.com

* Corresponding author

Published: 01 August 2003

Received: 19 January 2003

World Journal of Surgical Oncology 2003, 1:13

Accepted: 01 August 2003

This article is available from: <http://www.wjso.com/content/1/1/13>

© 2003 Chintamani et al; licensee BioMed Central Ltd. This is an Open Access article: verbatim copying and redistribution of this article are permitted in all media for any purpose, provided this notice is preserved along with the article's original URL.

Abstract

Background: Sweat gland adenocarcinoma is a rare malignancy with high metastatic potential seen more commonly in later years of life. Scalp is the most common site of occurrence and it usually spreads to lymph nodes. Liver, lung and bones are the distant sites of metastasis with fatal results. The differentiation between apocrine and eccrine metastatic sweat gland carcinoma is often difficult. The criteria's are inadequate to be of any practical utility.

Case Report: Two cases of metastatic sweat gland adenocarcinoma (one of eccrine and the other one of apocrine origin) are being reported on account of the rarity and different outcome.

Conclusion: Sweat gland carcinomas are rare cancers with a poor prognosis often presenting as histological surprises. Surgery in the form of wide local excision and lymph node dissection is the mainstay of treatment. Chemotherapy and/or radiotherapy has limited role.

Introduction

Sweat gland neoplasms (microcystic adenexal carcinoma) are rare with approximately 200 cases of eccrine sweat gland and 38 cases of apocrine gland carcinoma being reported in the world literature [1,2]. It is often not diagnosed clinically or incorrectly and is encountered as a histological surprise i.e. as an incidental finding at histology of resected specimen. A wide surgical excision is the treatment of choice with clearance of draining lymph nodes. The role of adjuvant chemotherapy and radiotherapy is not established. We report here two cases of sweat gland adenocarcinoma one each of eccrine and apocrine origin.

Case Report

Case 1

A 45-year-old man presented to the surgical wing with swelling in the right axilla of 2 months duration. There was a past history of pulmonary tuberculosis, two years back, for which patient had taken anti tubercular treatment. On examination the thyroid, breasts, chest, abdomen, and per rectal examinations were normal. Examination of axilla revealed a tiny, indurated, non tender, pink skin nodule of about 5 mm diameter (figure 1) with multiple, firm, non tender, discrete, axillary lymph nodes measuring 1 to 4 cm.

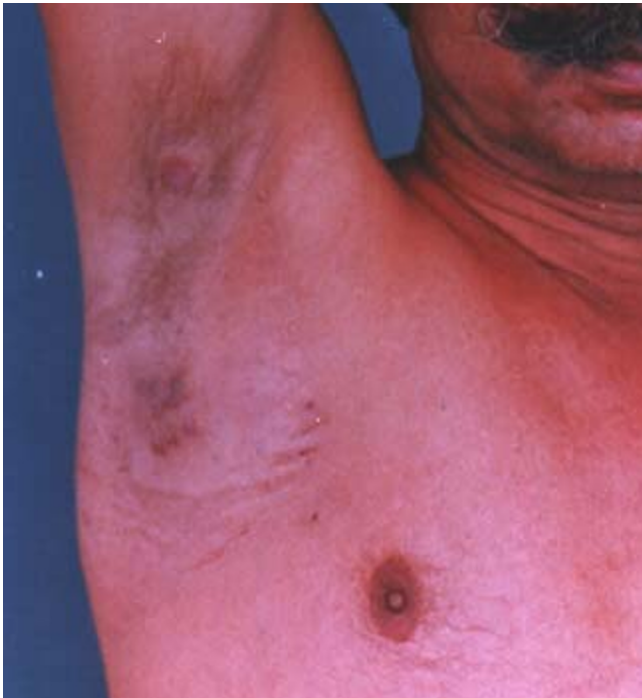

Figure 1
Clinical photograph showing right axillary fullness and skin nodule

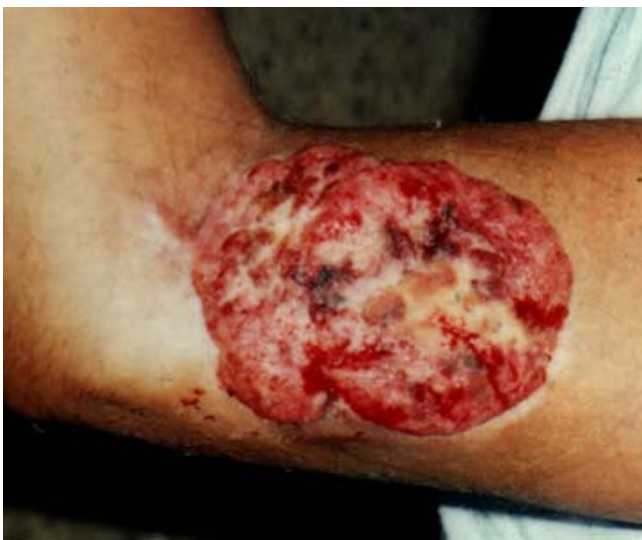

Figure 3
Clinical photograph showing recurrent sweat gland adenocarcinoma on the arm.

Hematological and biochemical investigations were within normal limits. Chest roentgenogram showed healed tubercular lesion in right apical area. A contrast enhanced computerized tomographic scan (CECT) of the chest and fiber optic bronchoscopy was carried out which did not reveal any significant pathology except healed fibro cavitary lesion in the right apex. Ultrasound examination of both the breasts, and abdomen was essentially normal. Fine needle aspiration cytology (FNAC) from the axillary lymph node revealed metastatic adenocarcinoma. Excision biopsy of the lymph node and suspected primary skin lesion was performed which revealed metastatic sweat gland adenocarcinoma with solid and glandular pattern (figure 2). The tumor cells were Periodic Acid Schiff (PAS) positive, diastase sensitive and were estrogen receptor negative. A diagnosis of sweat gland adenocarcinoma, probably of eccrine origin was made. An axillary lymph node dissection along with excision of the previous scar was carried out. While raising the upper skin flap two-satellite cutaneous nodules each measuring, 2-3 mm in diameter, were found and were excised *en bloc*. Histological examination of the resected specimen confirmed the diagnosis of metastatic sweat gland adenocarcinoma of eccrine origin. Patient had an uneventful recovery and is disease free after two years of follow-up.

Case 2

A 20-year-old man presented with a 10 × 8 cm recurrent exophytic growth on the ventral lower aspect of the right arm partly overlying ante cubital fossa (Figure 3). The swelling was tender and fixed to underlying structures. Axillary lymphadenopathy was present. The patient had undergone excision biopsy for a nodular growth in the same area four months earlier. An incision biopsy was taken which was reported as sweat gland adenocarcinoma of apocrine origin. A FNAC from the axillary lymph node confirmed axillary metastasis from the same neoplasm. There was no evidence of distant metastasis. Patient was treated by wide excision and skin grafting of the primary lesion along with axillary lymph node dissection. Histological examination of the resected specimen showed the tumor to be PAS positive and diastase resistant confirming the diagnosis of sweat gland adenocarcinoma of the apocrine origin, resected margins were free and the lymph nodes were involved (figure 4, &5). Patient was asymptomatic for two months following which he developed local recurrence and was taken up for re-excision. At second surgery the tumor was found to infiltrate the neurovascular bundles of the arm and humerus. In order to achieve an R0 resection a mid arm amputation was performed and the patient was referred for postoperative adjuvant treatment. He received adjuvant chemotherapy in form of 5-fluorouracil, and cis-platininum followed by 70 Gy of external beam radiotherapy to the stump and 50 Gy of radiotherapy to axilla. Patient was disease free for six

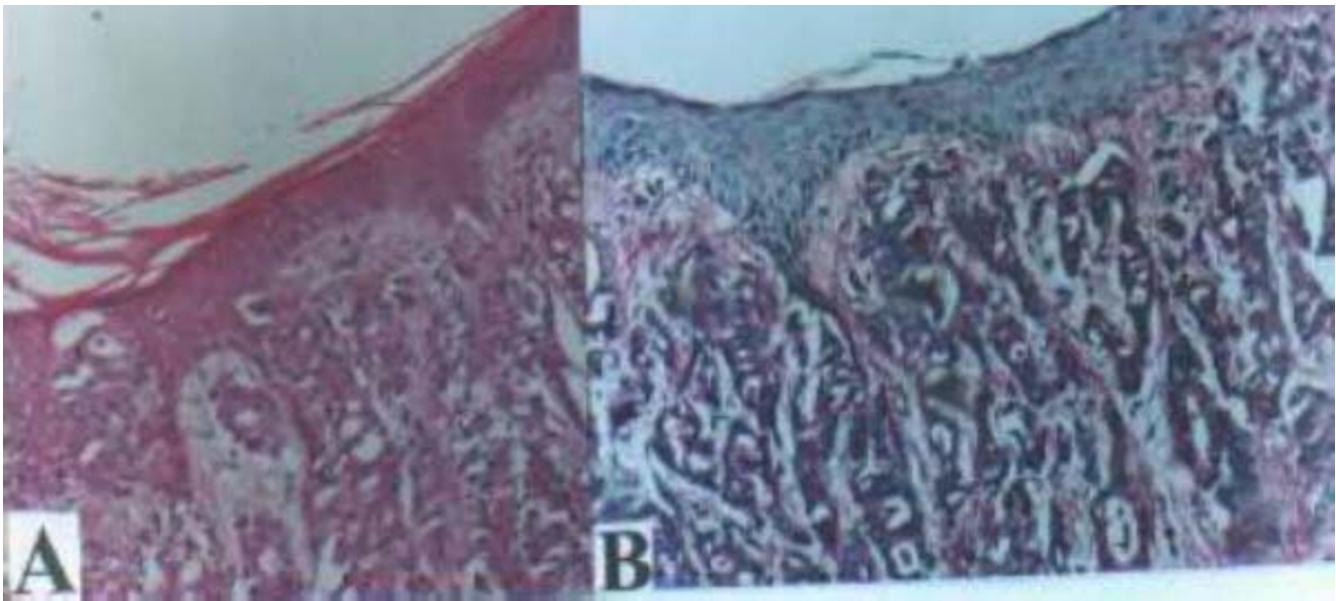


Figure 2
Photomicrograph of sweat gland carcinoma (Hematoxyllin and eosin $\times 10$) Figure 2A: Showing glandular pattern with dermal invasion ((Hematoxyllin and eosin $\times 10$) Figure 2B: Diastase sensitive, PAS positive tumor cells (PAS $\times 10$)

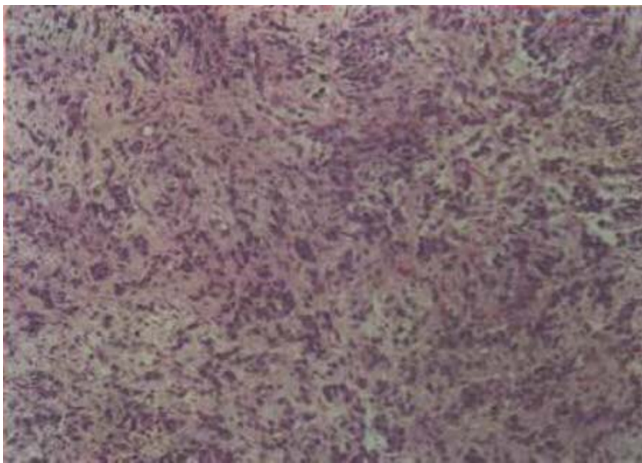


Figure 4
Photomicrograph showing the tumor cells loosely infiltrating the stroma (Hematoxyllin and eosin $\times 10$)




Figure 5
Photomicrograph showing lymph node metastases (Hematoxyllin and eosin $\times 10$)

months there after he developed pulmonary metastasis, pleural effusion, and axillary recurrence. He was breathless, comatose and severely dehydrated thus managed by supportive and palliative treatment and died. Unlike the first case this patient died from disease within ten months of the initiation of the disease process.

Discussion

Sweat gland carcinoma represent a rare group of tumors with potential for destructive local tissue infiltration and regional as well as distant metastasis. The management of these neoplasms is both complex and cumbersome, mainly due to limited availability of literature. Histologi-

cal resemblance to the mature gland in biopsy specimen too contributes. The diagnosis is primarily based on histochemical, immunochemical, or ultrastructural features. These tumors therefore can be considered as clinico-pathological dilemmas with an unpredictable biological behavior. Rarely diagnosed clinically, they are often encountered as operative and histological surprises [1-5].

The two basic types of sweat glands in the humans are eccrine and apocrine. The eccrine glands are present everywhere, except the lips, glans penis, inner surface of the prepuce, clitoris and labia minora. They are most dense on palms and soles and respond primarily to cholinergic stimuli, thereby playing an important role in regulating the body temperature.

The apocrine sweat glands are limited to ear canal, the eyelids, the axilla, the anogenital region and the mammary areola and are under the control of sexual hormones [2,5-7]. The tumor was first described by Goldstein in 1982 [8] and originates from pluripotent adnexal cells capable of eccrine and follicular differentiation. There is an orderly progression of spread to regional lymph nodes and distant sites with metastatic adenocarcinomas carrying a poor prognosis.

Division of sweat gland carcinomas into eccrine and apocrine groups, although desirable, is not clinically useful as the existing literature has not adequately subdivided and studied the separate entities well enough to make this distinction worthwhile. Sweat gland carcinomas occur primarily in adult patients, with a peak incidence in fifth and sixth decades of life [2,6,7]. Majority occur in the genital skin and perineum (34.5%), followed by trunk (26.4%), head and neck (18.3%) and lower extremities (13.9%) [2,5,6,9].

The two main subtypes of sweat gland carcinomas are apocrine gland carcinomas and eccrine carcinomas. Apocrine carcinomas manifest as non-tender single or multiple, firm, rubbery or cystic masses with red to purple overlying skin [2,5,9]. Microscopically they have appearance of an adenocarcinoma with well-developed glandular lumina, showing characteristic evidence of "decapitation secretion". Tumor cells are PAS positive due to glycogen granules and diastase resistant [2]. Other features include glandular lumen, which may be narrow or slightly dilated with the cells of glandular and papillary structures being large, with a strongly eosinophilic cytoplasm containing hemosiderin. Sudan stain for lipids may be either negative or positive with mucin often being present in the lumen of the glandular structures and also around them.

Eccrine gland carcinomas possess no distinctive clinical features making diagnosis by gross appearance virtually impossible. They usually manifest as non-tender, subcutaneous nodules, primarily in elderly individuals. Individual malignant cells are rich in glycogen and stain with PAS and are diastase sensitive with prevalent nuclear changes and propensity for lymphatic invasion [7,9]. The glandular features show narrow lumen surrounded by a layer of flat or cuboidal cells with no hemosiderin. PAS stain after diastase digestion shows the tubular structures are not surrounded by a basement membrane but rather by a strongly stained cuticle containing amorphous masses in their lumen [5,7,9-11].

Sweat Gland Carcinomas Are Broadly Divided In To [9,12,13]

1. Tumors bearing resemblance to their benign counterparts are designated accordingly
2. Those without or minimal resemblance to their benign counterparts are further classified in to:

(A). Eccrine adenocarcinomas: These generally resemble a moderately to poorly differentiated adenocarcinoma, with regional variation ranging from true ductules in some areas to infiltrative, nonglandular anaplastic cells to glycogenated cellular zones in other areas. Contiguity with benign eccrine structures or with overlying epidermis is not seen.

(B) Mucinous eccrine carcinomas are characterized histologically by solitary and nested anaplastic cells floating in pools of mucin within the dermis. Thin strands of fibrous tissue serve to compartmentalize these "lakes" of mucin.

(C) Adenoid cystic eccrine carcinomas: These are seen as tumors of major and minor salivary glands but rarely may be encountered as primary cutaneous tumors remote from salivary apparatus. These tumors exhibit a population of uniform basaloid cells forming cribriform and tubular structures, usually with evidence of mucin and hyaline surrounding cellular masses. Perineural invasion is prevalent and should be looked for specifically.

(D) Aggressive digital papillary adenoma/carcinoma: These tumors exhibit cystic zones manifesting papillary infoldings and lined with benign cuboidal epithelium, more cellular zones of atypical adenomatous hyperplasia, and areas of overt adenocarcinoma. It is questionable whether aggressive digital papillary adenoma (ADPA) can be distinguished histologically from aggressive digital papillary adenocarcinoma. It is recommended that all aggressive digital papillary (ADP) tumors be designated and managed as "adenocarcinomas" [9,11,12]

Sites of sweat gland carcinoma metastasis include nodes, lungs, liver and bone [2,9,13]. Metastatic deposits from undiagnosed visceral and breast adenocarcinoma are virtually indistinguishable microscopically from sweat gland carcinoma and must be considered before a diagnosis of metastatic sweat gland carcinoma is made. Breast cancer is differentiated by negative PAS staining and positive estrogen, progesterone receptor staining.

The recommended treatment of all subtypes of sweat gland carcinomas is wide surgical excision along with regional lymph node dissection in the presence of clinically positive nodes. Some authors advocate prophylactic regional lymph node dissection especially in patients with recurrent lesions after wide excision or with highly undifferentiated tumors. Sweat gland carcinomas are radioresistant and chemotherapy has been infrequently employed [14]. Prognostic factors for sweat gland carcinoma are difficult to identify, again owing to the small number of reported cases. The likely prognostic factors include size, histological type, lymph node involvement and distant metastasis. A 10-year disease free survival rate of 56% in the absence of lymph node metastasis is observed which falls to 9% if nodes are involved [2,12-14].

References

1. Doley B, Das AK and Das M: **Metastatic sweat gland carcinoma** *J Assoc Physician India* 2001, **49**:479-480.
2. Mitts DL, Smith MT, Russell L, Bannayan GA and Cruz AB Jr: **Sweat gland adenocarcinoma: a clinico-pathological reappraisal** *J Surg Oncol* 1976, **8**:23-29.
3. Yildirim S, Akoz T, Akan M and Ege GA: **De novo malignant eccrine spiradenoma with an interesting and unusual location** *Dermatol Surg* 2001, **27**:417-420.
4. Urso C, Bondi R, Paglierani M, Salvadori A, Anichini C and Giannini A: **Carcinomas of sweat gland: report of 60 cases** *Arch Pathol Lab Med* 2001, **125**:498-505.
5. Vaideeswar P, Madhiwale CV and Deshpande JR: **Malignant hidradenoma: a rare sweat gland tumor** *J Postgrad Med* 1999, **45**:56-57.
6. Panoussopoulos D, Darom A, Lazaris A, Misthos P, Papadimitrion K and Androulakis G: **Sweat gland carcinoma with multiple local recurrences: a case report** *Adv Clin Path* 1999, **3**:63-68.
7. Snow S, Madjar DD, Hardy S, Bentz M, Lucarelli MJ, Bechard R, Aughenbaugh W, McFadden T, Sharata H, Dudley C and Landeck A: **Microcystic adenexal carcinoma: report of 13 cases and review of the literature** *Dermatol Surg* 2001, **27**:401-408.
8. Goldstein DJ, Barr RJ and Santa Cruz DJ: **Microcystic adenexal carcinoma: a distinct clinicopathologic entity** *Cancer* 1982, **50**:566-572.
9. Hashimoto K: **Adnexal carcinoma of skin** In *Cancer of Skin* Edited by: *Freidman RJ, Rigel DS, Kopf AW. Philadelphia, WB Saunders; 1991:209-216.*
10. Maroske J, Gassel HJ, Navarro-Peredes E, Ziegler U and Thiede A: **Sweat gland carcinoma in the axillary area. A case report with review of literature** *Chirurg* 2001, **72**:190-192.
11. Hashimoto K, Mehregam AH and Kumakiri M: **Tumors of skin appendages** *Boston, Butterworths* 1987:208.
12. el-Domeiri AA, Brasfield RD, Huvos AG and Strong EW: **Sweat gland carcinoma: a clinico-pathological study of 83 patients** *Am Surg* 1971, **173**:270-274.
13. Wick MR and Coffin CM: **Sweat gland and pilar carcinoma** In *Pathophysiology of unusual malignant cutaneous tumors* Edited by: *Wick MR. New York, Marcel Dekker; 1985:1-76.*
14. Morabito A, Benlaqua P, Vitale S, Fanelli M, Gattuso D and Gasparini G: **Clinical management of a case of recurrent apocrine**

gland carcinoma of the scalp: efficacy of a chemotherapy schedule with methotrexate and bleomycin *Tumori* 2000, **86**:472-474.

Publish with **BioMed Central** and every scientist can read your work free of charge

"BioMed Central will be the most significant development for disseminating the results of biomedical research in our lifetime."

Sir Paul Nurse, Cancer Research UK

Your research papers will be:

- available free of charge to the entire biomedical community
- peer reviewed and published immediately upon acceptance
- cited in PubMed and archived on PubMed Central
- yours — you keep the copyright

Submit your manuscript here:
http://www.biomedcentral.com/info/publishing_adv.asp

